

Ventricular Tachycardia

History

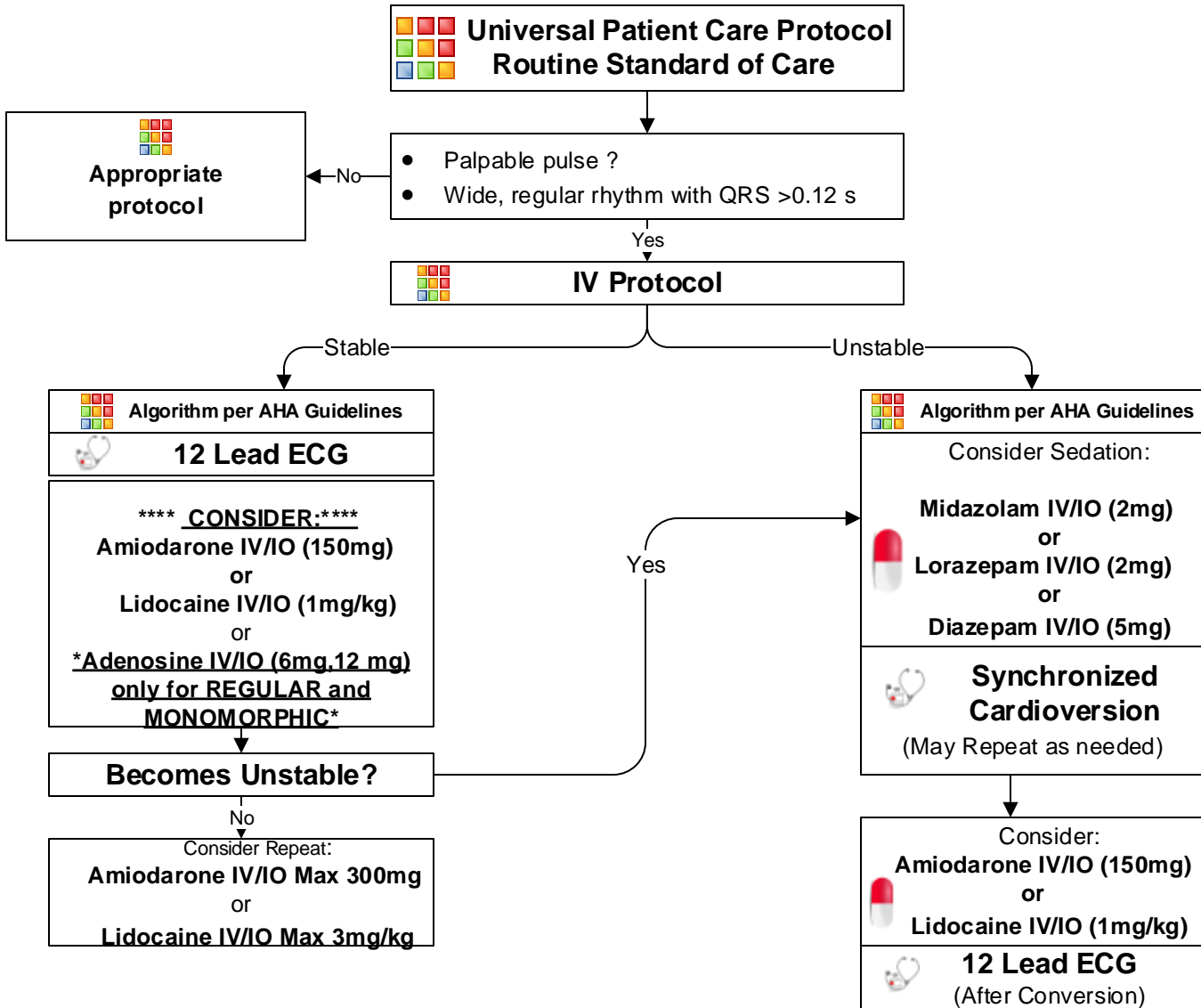
- **SAMPLE**
- Medications, diet, drugs.
- Syncope / near syncope
- CHF
- Palpitations
- Pacemaker
- Allergies: lidocaine / novacaine

Signs and Symptoms

- Ventricular tachycardia on ECG (Runs or sustained)
- Conscious, rapid pulse
- Chest pain, shortness of breath
- Dizziness
- Rate usually 150 - 180 bpm for sustained V-Tach
- **QRS > .12 Sec**

Differential

- **Artifact / Device failure**
- **Cardiac**
- **Endocrine / Metabolic**
- **Drugs**
- **Pulmonary**



Pearls

- **Recommended Exam: Mental Status, Skin, Neck, Lung, Heart, Abdomen, Back, Extremities, Neuro**
- For witnessed / monitored ventricular tachycardia, try having patient cough.
- Polymorphic V-Tach (Torsades de Pointes) may benefit from the administration of Magnesium Sulfate if available.
- If presumed hyperkalemia (end-stage renal disease, dialysis, etc.), administer Sodium Bicarbonate.